ARTICLE IN PRESS

Journal of Pediatric Surgery xxx (2016) xxx–xxx

Contents lists available at ScienceDirect

Journal of Pediatric Surgery

journal homepage: www.elsevier.com/locate/jpedsurg

Efficacy and safety of ultrasound-guided internal jugular vein catheterization in low birth weight newborn

Fernando Montes-Tapia [a,*], Antonio Rodríguez-Taméz [a], Idalia Cura-Esquivel [a], Itzel Barreto-Arroyo [a], Adolfo Hernández-Garduño [a], Isaías Rodríguez-Balderrama [a], José Quero [b], Manuel de la O-Cavazos [a]

[a] Department of Pediatrics, Hospital Universitario, Universidad Autónoma de Nuevo León, Av. Madero y Gonzalitos s/n, Monterrey, N.L. 66451
[b] Facultad de Medicina, Universidad Autónoma de Madrid, C/Arzobispo Morcillo 4 Madrid, Madrid, ES 28029

ARTICLE INFO

Article history:
Received 1 March 2016
Received in revised form 16 May 2016
Accepted 21 May 2016
Available online xxxx

Key words:
Internal jugular vein
Catheterization
Ultrasound
Low-birth weight newborn

ABSTRACT

Background: Central venous catheterization is not the first choice of vascular access in neonates. Success depends on the size of the vessel and the skill of the health professional performing the procedure. The internal jugular vein provides a predictable path for central venous cannulation, although it is more difficult to cannulate infants than adults and even more difficult in smaller newborns.
Methods: We conducted a prospective study in 100 newborns, in which a 4 Fr ultrasound-guided central venous catheter was placed in the right internal jugular vein (RIJV). The study population was low birth weight (LBW) newborns <2500 g, very low birth weight (VLBW) newborns <1500 g and extremely low birth weight (ELBW) newborns <1000 g.
Results: There were 53% female patients, mean gestational age was 31 weeks, mean weight 1352 g and the CVC was placed at a mean of 12 days of extrauterine life. Birth weight distribution was 39% LBW; 33% VLBW and 28% ELBW. A mean of two (1–8) attempts were necessary with a procedure duration of 16.8 (10–40) minutes. Success of RIJV catheterization was 94%. One attempt was necessary in 50% and up to 5 attempts in 95.7%. Success by weight was VLBW, 97.2%; ELBW, 92.9%; LBW, 91.7%. A venous hematoma occurred in 5% of cases.
Conclusions: Ultrasound-guided RIJV cannulation with real-time visualization to gain access to the central venous circulation in low birth weight newborns is effective and safe.

The most frequently performed invasive procedure in a neonatal intensive care unit is placement of an intravascular catheter [1]. With the advancements in technology and better prenatal care and neonatal therapy, the survival of low weight newborn patients is greater every day. Some of these infants will require a catheter for monitoring blood pressure, drawing blood samples, and delivering fluids and drugs [2,3].

Central venous catheterization is not the first choice of vascular access in neonates. The first choices include peripheral lines, umbilical catheters, and central venous access through a peripheral vein. Success in achieving these accesses depends on the size of the vessel and the skill of the health professional performing the procedure. When these options for venous access are not possible, a central venous line is considered [2,4,5].

Traditionally central lines are inserted in neonates by venous cutdown [6] or percutaneous puncture guided by anatomical reference. However, complications such as arterial puncture, pneumothorax, hemothorax and even death have occurred secondary to catheterization by anatomical references, making this a high-risk procedure [7].

The internal jugular vein (IJV) provides a predictable path for central venous cannulation, but in children, a failed attempt of catheterization of the RIJV guided by anatomical references is inversely proportional to age, and it occurs in up to 60% of infants less than 3 months of age compared with adult patient populations (16%) [8–10].

According to reports in the literature, anatomic factors are among the most frequent causes of failure of percutaneous insertion of a CVC, since in low birth weight newborns, the muscle and bone reference points are often difficult to palpate or locate [11,12].

In adults, percutaneous catheterization guided by ultrasound has been widely reported and is today the technique of choice because of its efficacy and low complication rate [13,14]. In pediatric patients, the benefits of using ultrasound for the placement of a central venous access have also been demonstrated when compared with using anatomical references [15–19]. However, there are no data evaluating low weight newborns.

The objective of this study was to evaluate the efficacy and safety of ultrasound-guided RIJV access in a population of low-weight newborns attended in a neonatal intensive care unit in an academic teaching hospital in northeast Mexico.

* Corresponding author at: Universidad Autónoma de Nuevo Leon, Departamento de Pediatria, Hospital Universitario "Dr. José E. Gonzalez", Av. Madero y Gonzalitos s/n, Monterrey, Nuevo Leon, Mexico, CP64360.
E-mail address: fernando.montestp@uanl.edu.mx (F. Montes-Tapia).

http://dx.doi.org/10.1016/j.jpedsurg.2016.05.014
0022-3468/

Please cite this article as: Montes-Tapia F, et al, Efficacy and safety of ultrasound-guided internal jugular vein catheterization in low birth weight newborn, J Pediatr Surg (2016), http://dx.doi.org/10.1016/j.jpedsurg.2016.05.014

1. Methods

Newborns with a body weight less than 2500 g were included. A central venous catheter (CVC) was requested after conventional vascular accesses (umbilical, peripheral or femoral) had failed. The same pediatric surgeon (FMT) performed all ultrasound evaluations and procedures of the RIJV. The study was previously approved by the Institutional Ethics Committee (PE006) and in all cases; parent informed consent was obtained before the procedure. Newborns with any type of right cervical lesion were excluded. Those who had not undergone a RIJV ultrasound evaluation before the procedure were eliminated.

The study variables were gestational age and weight. Newborns were classified in three groups: low birth weight (LBW) newborns, 1501 to 2500 g; very low birth weight (VLBW) newborns, 1001 to 1500 g; and extremely low birth weight (ELBW) newborns <1000 g.; data regarding sex, diagnosis, days of extrauterine life and type of ventilation, were recorded.

A MicroMaxx (Sonosite, Inc., Bothell, WA) portable ultrasound with a 4–8 Mhz transducer was used. Evaluation and vascular access were performed with the transducer in short-axis view (SAX), viewing the RIJV cross-sectionally. The time required for placement of the catheter was recorded, from the moment a sterile field was placed until fixation of the catheter to the skin. Also, the number of attempts needed for placement and the complications associated with the procedure were recorded.

1.1. Insertion technique

The patient was sedated intravenously with midazolam and fentanyl and placed in a supine position with a roll under the shoulders and the head rotated 40° to the left. In VLBW and ELBW infants, the skin over the RIJV is stretched upwards with Micropore® (3M Company, Two Harbors, MI) in the cephalic and caudal directions. The skin traction method was performed to prevent collapse of the internal jugular vein [20] (Fig. 1). A 4 Fr. double lumen CVC was used, however the length varies according to availability in the hospital, 4 cm and 8 cm Cook Spectrum (Cook ® Cook Critical Care, Bloomington, IN) or 13 cm (Arrow ® International, Inc. USA).

Fig. 1. The skin traction method in a patient of 740 g, the skin over the RIJV is stretched upwards with Micropore® in the cephalic and caudal directions.

Using an aseptic technique, sterile dressing and local anesthesia with 1% lidocaine, a puncture was made with real-time ultrasound guidance.

RIJV puncture was done by transfixion with a short 22-gauge intravenous catheter for LBW infants and a 24-gauge in VLBW and ELBW infants (Fig. 2). A 0.018″ guidewire was used in LBW infants and a Runthrough™ 0.014″ intravascular microguide (Terumo Medical Corporation, Japan) in VLBW and ELBW infants. A different caliber guidewire was used to ensure canalization of the RIJV in very small infants.

The catheter was introduced using the Seldinger technique and it was fixed with 4-0 polypropylene. A chest X-ray was taken to confirm the location of the catheter tip.

1.2. Statistical method

Statistical analysis was performed using IBM Statistics 19 for Windows.

Continuous variables were reported measures of central tendency and dispersion; and proportions for nominal or categorical variables. A stratified analysis based on body weight was performed according to the three groups (LBW, VLBW and ELBW). For the variable number of attempts and success of the procedure of placing a CVC in the RIJV, a comparative analysis was performed according to the weight of the subjects using the Mann–Whitney test, considering a P value < .05 as a statistically significant difference.

2. Results

One hundred newborns with a birth weight below 2500 g were included during the period of August 2009 to December 2011. Of the total, 53% were females. According to gestational age, 96% were premature, and of these, 19% were extremely premature. Mean gestational age was 31 ± 3.3 weeks; mean weight was 1352 ± 458 g, and CVC placement was at 12 ± 14 days of extrauterine life. Based on weight, 39% were LBW infants (1501–2480 g), 33% were VLBW infants (1030–1470 g), and 28% were ELBW infants (540–960 g). At the time of the procedure, 73% had assisted ventilation. The diagnoses at the moment of CVC placement were sepsis 39%, hyaline membrane disease 23%, necrotizing enterocolitis 14%, postsurgical 10%, and other diagnoses in 14%.

The anteroposterior cross-sectional diameter of the RIJV in the study population was 2.2 ± 0.7 mm with a distance from the skin to the anterior wall of the vein of 3.6 ± 1.1 mm [21]. A median of 2 (1–8) attempts was performed to achieve RIJV canalization, with the mean duration of the procedure being 16.8 (10–40) minutes. The overall success rate of CVC placement in the RIJV was 94%. Failure occurred in 6 patients (6%). Of these, in five patients (5%), a non-pulsatile, non-expanding hematoma of the puncture site was found and failure to pass the guidewire occurred in one patient (1%). All cases of hematoma were associated with puncture of the RIJV and none with puncture of the carotid. There were no cases of pneumothorax or hemothorax. Of the 94 patients in which canalization of the RIJV was achieved, in 47 (50%) it was accomplished on the first puncture and in up to 5 attempts, 43 more newborns were cannulated successfully, with an accumulated success rate of 95.7% (Table 1).

In the six patients in which the procedure originally failed, the CVC was placed in the left internal jugular vein in 2, the right femoral vein in 2, the right subclavian vein in 1 and in the left subclavian vein in 1.

2.1. Procedure success by groups

The procedure was successful in 92.3% (n = 36) in the LBW group (n = 39) and was accomplished on the first attempt in 55.6% (n = 20) and after up to five attempts in 97.2% (n = 35). In VLBW (n = 33) infants, the procedure was successful in 97% (n = 32) and was accomplished on the first attempt in 43.8% (n = 14) and after up to five

Please cite this article as: Montes-Tapia F, et al, Efficacy and safety of ultrasound-guided internal jugular vein catheterization in low birth weight newborn, J Pediatr Surg (2016), http://dx.doi.org/10.1016/j.jpedsurg.2016.05.014

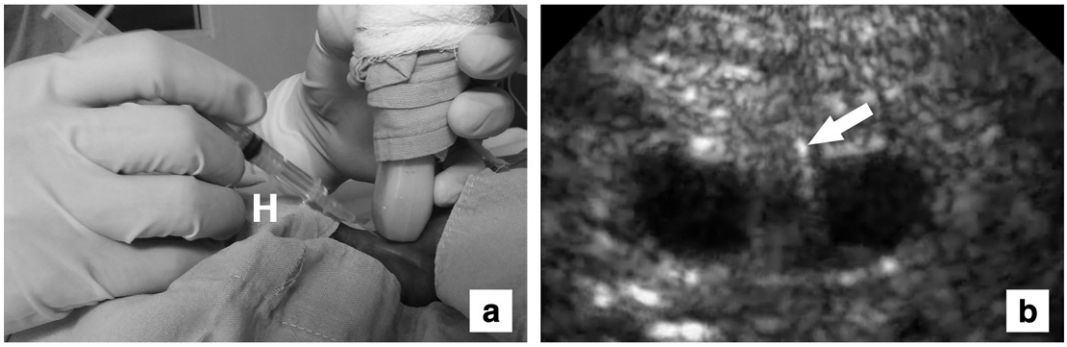

Fig. 2. a. The punction in the patient of Fig. 1 with a short 24-gauge intravenous catheter. b. The ultrasound image represents the short 24-gauge intravenous catheter tip (arrow) inside the right internal jugular vein.

attempts in 100% (n = 32). In the ELBW group (n = 28), the procedure was successful in 92.9% (n = 26) and was accomplished on the first attempt in 50% (n = 13), and after up to five attempts in 88.5% (n = 23) (Table 2).

2.2. Procedure failure by groups

LBW infants had the greatest number of procedure failures with 3 (7.7%), followed by ELBW infants with 2 (7.1%). All were secondary to a venous hematoma. This was the cause of failure of canalization of the RIJV after a mean of seven attempts in the LBW group and after five in the ELBW group. In the VLBW group, only one patient had a procedure failure because the guidewire could not be passed. There were no deaths associated with the procedure.

3. Discussion

This study presents a population of 100 newborns with a weight range from 540 g to 2480 g with 96% being premature, conditions that carry a high risk of morbidity and mortality [22]. The efficacy of ultrasound-guided RIJV catheterization in our study was 94%. Arul et al. [23] reported 100% success in a population of infants with a mean weight of 2900 g, but in our study patients had a lower mean weight of 1352 g. In the present report, the group that had the greatest success in CVC canalization was VLBW infants (97%), followed by the ELBW group (92.9%) and the LBW group (92.3%) with no statistical difference. We have not found previous reports of newborn populations stratified as in this study, only isolated clinical cases or cases reports that mention the feasibility of ultrasound-guided IJV access [23–25].

The number of attempts needed to canalize the RIJV was a mean of two. We canalized 50% of newborns on the first attempt and 95.7% after up to 5 attempts.

The group with the greatest success on the first puncture was LBW infants (55.6%); the main reason they probably achieved canalization on the first puncture was their greater weight, and also, possibly because of the larger RIJV diameter compared to ELBW (50%) and VLBW infants (43.8%) [21].

Table 1
Correlation between number of attempts and procedure success.

Attempts	Cases n = 94	Success rate (%)	Accumulated success (%)
1	47	50	50
2	18	19.1	69.1
3	14	14.9	84
4	6	6.4	90.4
5	5	5.3	95.7
6	3	3.2	98.9
8	1	1.1	100
Total	94	100	

Although there is no literature that quantifies the number of attempts to achieve canalization of the RIJV in a similar population, in pediatric patient publications, the range is wide, although up to 7 attempts for percutaneous catheterization have been reported [26–30]. In this study, the only case that required eight attempts was in a newborn weighing 690 g and this was owing to technical problems related to the guidewire because of the small vessel diameter.

A parameter that must be determined is the time it takes to perform the procedure; however, there is no established standard; i.e., there are studies that only measure the time needed to canalize the vein (12 s), while others measure the time from puncture to CVC placement (4.5 min) [28,30–32]. In the present report, the mean time to perform canalization was 16 ± 6 min. The reason for the longer time was that we measured the total time from placement of sterile fields to fixation of the catheter with suture and placement of the adhesive patch. We did not find differences in procedure time between the groups. Verghese et al. [27] reported that after 45 min of trying to canalize the vein, this route should be abandoned. In our group the maximum procedure time was 40 min.

Failure to achieve canalization of the RIJV occurred in six patients; in five because of a venous hematoma, which caused collapse and/or vasoconstriction of the RIJV. There is a direct relationship between the number of attempts and complications such as thrombosis, sepsis, and puncture of adjacent structures, especially the carotid. In the literature, attempts performed using anatomical references reported carotid puncture in 8.5% to 25% [27,32,33].

Table 2
Number of attempts by group, frequency and success.

Group	Attempts (#)	Frequency	Success (%)	Accumulated success (%)
LBW, n = 36	1	20	55.6	55.6
	2	7	19.4	75.0
	3	5	13.9	88.9
	5	3	8.3	97.2
	6	1	2.8	100
	Total	36	100	
VLBW, n = 32	1	14	43.8	43.8
	2	7	21.9	65.7
	3	5	15.6	81.3
	4	5	15.6	96.9
	5	1	3.1	100
	Total	32	100	
ELBW, n = 26	1	13	50	50
	2	4	15.4	65.4
	3	4	15.4	80.8
	4	1	3.8	84.6
	5	1	3.8	88.5
	6	2	7.7	96.2
	8	1	3.8	100
	Total	26	100	

LBW: low birth weight; VLBW: very low birth weight; ELBW: extremely low birth weight.

Please cite this article as: Montes-Tapia F, et al, Efficacy and safety of ultrasound-guided internal jugular vein catheterization in low birth weight newborn, J Pediatr Surg (2016), http://dx.doi.org/10.1016/j.jpedsurg.2016.05.014

In our study, we knew that no hematoma was secondary to arterial puncture because the punctures were guided by ultrasound (in real time) and because of the characteristics of the hematoma (non-pulsatile and non-expanding).

In the group of LBW and ELBW infants, we found a mean of 7 and 5 attempts, respectively, with the complication of a RIJV hematoma. It is important to consider that attempts or any nociceptive action in these groups of patients can cause damage to the cardiovascular and neurological system; therefore, as in peripheral access, a maximum of five attempts would be the best recommendation to change to another anatomical site; also, this procedure should always be performed with good pain control.

Sigaut et al. [34] reported that there is little benefit in using ultrasound for those who have experience in percutaneous canalization, but in individuals with less experience it is useful to acquire the skill. However, this analysis was conducted only in studies with patients older than 1 month and did not include low birth weight or premature newborns. In the present study, operator experience was an important variable for success of the procedure. Since the first author has experience in catheter placement using anatomical references and also use of ultrasound for vascular access in pediatric patients [21,35] but not in infants <2500 g, we believe that this experience produced a lower learning curve than if he had been naive in vascular access. On the other hand, the acquisition of skills and competence in vascular access in this group of infants (<2500 g), requires training and regular practice.

Another variable is technology, which is rapidly evolving. In the present report, we used a 8–4 MHz transducer; however, with the advent of more powerful computers and 13–6 MHz transducers, image quality will improve and smaller diameter veins will be accessible, although we will still have to wait for smaller diameter CVCs with more lumens.

The advantage of ultrasonographic assessment of the RIJV in a low birth weight newborn population is adequate visualization of structures before the puncture. With it, one can measure depth, vein diameter, intraluminal conditions (patency), and also determine anatomic variations and the relationship of the vein with the ipsilateral carotid artery. In conclusion, the greatest benefit of RIJV ultrasound guided cannulation with real time visualization in low birth weight newborns is the increase in efficacy and safety, while reducing complications.

Acknowledgements

We thank Sergio Lozano-Rodriguez, M.D. for his help in translating the manuscript and César Luna-Gurrola for his statistical assistance.

References

[1] Hermansen MC, Hermansen MG. Intravascular catheter complications in the neonatal intensive care unit. Clin Perinatol 2005;32:141–56.
[2] Ramasethu J. Complications of vascular catheters in the neonatal intensive care unit. Clin Perinatol 2008;35:199–222.
[3] Moro M, Figueras-Aloy J, Fernandez C, et al. Mortality for newborns of birthweight less than 1500 g in Spanish neonatal units (2002–2005). Am J Perinatol 2007;24:593–601.
[4] Detaille T, Pirotte T, Veyckemans F. Vascular access in the neonate. Best Pract Res Clin Anaesthesiol 2010;24:403–18.
[5] Donaldson JS. Pediatric vascular access. Pediatr Radiol 2006;36:386–97.
[6] Pandit PB, Pandit FA, Govan J, et al. Complications associated with surgically placed central venous catheters in low birth weight neonates. J Perinatol 1999;19:106–9.
[7] Wu J, Mu D. Vascular catheter-related complications in newborns. J Paediatr Child Health 2012;48:E91–5.
[8] Mallinson C, Bennett J, Hodgson P, et al. Position of the internal jugular vein in children. A study of the anatomy using ultrasonography. Paediatr Anaesth 1999;9:111–4.
[9] English ICV, Frew RM, Pigott JF, et al. Percutaneous catheterisation of the internal jugular vein. Anaesthesia 1969;24:521–31.
[10] Hayashi Y, Uchida O, Takaki O, et al. Internal jugular vein catheterization in infants undergoing cardiovascular surgery: An analysis of the factors influencing successful catheterization. Anesth Analg 1992;74:688–93.
[11] Eifinger F, Brisken K, Roth B, et al. Topographical anatomy of central venous system in extremely low-birth weight neonates less than 1000 grams and the effect of central venous catheter placement. Clin Anat 2011;24:711–6.
[12] Tailounie M, McAdams LA, Frost KC, et al. Dimension and overlap of femoral and neck blood vessels in neonates. Pediatr Crit Care Med 2012;13:312–7.
[13] NICE. Guidance on the Use of Ultrasound Locating Devices for Placing Central Venous Catheters: Technology Appraisal No. 49. National Institute for Clinical Excellence; 2002.
[14] Brass P, Hellmich M, Kolodziej L, et al. Ultrasound guidance versus anatomical landmarks for internal jugular vein catheterization. Cochrane Database Syst Rev 2015;1.
[15] Rey C, Alvarez F, De La Rua V, et al. Mechanical complications during central venous cannulations in pediatric patients. Intensive Care Med 2009;35:1438–43.
[16] Beagle GL. Bedside diagnostic ultrasound and therapeutic ultrasoundguided procedures in the intensive care setting. Crit Care Clin 2000;16:59–81.
[17] Alderson PJ, Burrows FA, Stemp LI, et al. Use of ultrasound to evaluate internal jugular vein anatomy and to facilitate central venous cannulation in pediatric patients. Br J Anaesth 1993;70:145–8.
[18] Hind D, Calvert N, McWilliams R, et al. Ultrasonic locating devices for central venous cannulation: meta-analysis. BMJ 2003;327:361.
[19] Bruzoni M, Slater BJ, Wall J, et al. A prospective randomized trial of ultrasound- vs landmark-guided central venous access in the pediatric population. J Am Coll Surg 2013;216:939–43.
[20] Sasano H, Morita M, Azami T, et al. Skintraction method prevents the collapse of the internal jugular vein caused by an ultrasound probe in real-time ultrasound-assisted guidance. J Anesth 2009;23:41–5.
[21] Montes-Tapia F, Rodriguez-Tamez A, Hernandez-Garduno A, et al. Vascular assessment of the right internal jugular vein in low birth weight newborns. J Matern Fetal Neonatal Med 2013;26:1510–3.
[22] Lawn JE, Cousens S, Zupan J, et al. 4 million neonatal deaths: When? Where? Why? Lancet 2005;365:891–900.
[23] Arul GS, Livingstone H, Bromley P, et al. Ultrasound-guided percutaneous insertion of 2.7 Fr tunnelled Broviac lines in neonates and small infants. Pediatr Surg Int 2010;26:815–8.
[24] Arul GS, Lewis N, Bromley P, et al. Ultrasound-guided percutaneous insertion of Hickman lines in children. Prospective study of 500 consecutive procedures. J Pediatr Surg 2009;44:1371–6.
[25] Machotta A, Kerner S, Höhne C, et al. Ultrasound-guided central venous cannulation in a very small preterm neonate. Paediatr Anaesth 2005;15:325–7.
[26] Johnson EM, Saltzman DA, Suh G, et al. Complications and risks of central venous catheter placement in children. Surgery 1998;124:911–6.
[27] Verghese ST, McGill WA, Patel RI, et al. Comparison of three techniques for internal jugular vein cannulation in infants. Paediatr Anaesth 2000;10:205–11.
[28] Nicolson SC, Sweeney MF, Moore RA, et al. Comparison of internal and external jugular cannulation of the central circulation in the pediatric patient. Crit Care Med 1985;13:747–9.
[29] Karapinar B, Cura A. Complications of central venous catheterization in critically ill children. Pediatr Int 2007;49:593–9.
[30] Asheim P, Mostad U, Aadahl P. Ultrasound-guided central venous cannulation in infants and children. Acta Anaesthesiol Scand 2002;46:390–2.
[31] Grebenik CR, Boyce A, Sinclair ME, et al. NICE guidelines for central venous catheterization in children. Is the evidence base sufficient? Br J Anaesth 2004;92:827–30.
[32] Verghese ST, McGill WA, Patel RI, et al. Ultrasound-guided internal jugular venous cannulation in infants. A prospective comparison with the traditional palpation method. Anesthesiology 1999;91:71–7.
[33] Coté CJ, Jobes DR, Schwartz AJ, et al. Two approaches to cannulation of a child's internal jugular vein. Anesthesiology 1979;50:371–3.
[34] Sigaut S, Skhiri A, Stany I, et al. Ultrasound guided internal jugular vein access in children and infant: a metaanalysis of published studies. Paediatr Anaesth 2009;19:1199–206.
[35] Montes-Tapia F, Rodríguez-Taméz A, Luévanos-Gurrola K, et al. Ultrasound- guided placement of double catheter in the right internal jugular vein: two case reports. Afr J Paediatr Surg 2014;11:196–8.

Please cite this article as: Montes-Tapia F, et al, Efficacy and safety of ultrasound-guided internal jugular vein catheterization in low birth weight newborn, J Pediatr Surg (2016), http://dx.doi.org/10.1016/j.jpedsurg.2016.05.014