Journal of Neonatal-Perinatal Medicine xx (20xx) x–xx
DOI:10.3233/NPM-180205
IOS Press

Original Research

Ultrasound guided central line insertion in neonates: Pain score results from a prospective study

R. Sabouneh[a], P. Akiki[a], A. Al Bizri[b], S. El Helou[a], S. Zeidan[c] and D. Al Hamod[a,*]
[a]*Department of Pediatrics, Division of Neonatology, Saint George Hospital University Medical Center, University of Balamand*
[b]*Department of Pediatrics, American University of Beirut Medical Center,*
[c]*Department of Pediatric Surgery, Saint George Hospital University Medical Center, University of Balamand, Beirut, Lebanon*

Received 12 December 2018
Revised 26 March 2019
Accepted 3 July 2019

Abstract.
BACKGROUND: Central lines can be placed through different techniques, either peripherally or centrally. Although they have the same aim, decision to use one of these modalities depends on the patient outcomes. The aim is to compare pain scores between ultrasound-guided central line insertion and peripherally inserted catheter in neonates in a prospective randomized single center study.
METHODS: A randomized controlled trial was conducted in neonates requiring central venous access for any of the following reasons: total parenteral nutrition (TPN), antibiotics treatment for at least 7 days and having poor or difficult venous access. The study compared pain difference, in neonates, that were randomized between peripherally and ultra-sound guided centrally placed central lines using the validated pain score N –PASS.
RESULTS: 61 neonates were enrolled in the study. US-guided CICC was associated with less pain as reported by the statistically significant lower pain score difference (p-value <0.001) than the standard PICC. Additionally, the US-guided CICC had a higher rate of successful first attempt ($p = 0.012$), lower overall number of attempts ($p < 0.001$), and shorter procedure duration ($p < 0.001$) as compared to standard PICC.
CONCLUSION: US-guided CICC is a less painful technique than PICC line insertion associated with higher rate of successful first attempt, lower overall number of attempts and shorter procedure duration.

Keywords: Central line, internal jugular vein, peripherally inserted central catheter, preterm neonates, ultrasound, pain score

Abbreviations

US	Ultrasound
PICC	Peripherally inserted central catheter
CICC	Centrally inserted central catheter
TPN	Total parenteral nutrition

*Address for correspondence: Dany Al Hamod, MD, Department of Pediatrics, Division of Neonatology, Saint George hospital University Medical Center, P.O. Box 166378, Ashrafieh, Beirut, Lebanon. E-mail: dany_alhamod@hotmail.com.

CVP	Central venous pressure
ECC	Epicutaneo-cava-catheter
IJV	Internal jugular vein
CVCs	Central venous catheters
N–PASS	Neonatal Pain, Agitation and Sedation Scale
NICU	Neonatal intensive care unit

1. Introduction

Central venous access is an imperative measure used in neonates whether being a perioperative measure for children undergoing cardiac procedures for congenital heart diseases or as a mean of nutrition in neonatal enteral malnutrition and drug administration in oncologic patients [1]. Central catheters fall into two categories, a peripherally inserted central catheter (PICC) line or centrally inserted central catheters (CICC). Although these two modalities practically have the same aim, identifying the more effective technique is imperative for deciding which procedure should be applied to ameliorate patient outcomes [2]. Many studies have been previously done that delineate the indications for central venous access with practically no absolute contraindications [3]. These indications include central venous pressure (CVP) monitoring, poor venous access, volume resuscitation, and prolonged venous access in critically ill patients, total parenteral nutrition (TPN), cardio-pulmonary resuscitation and medication administration [4]. Centrally inserted catheters have evolved from being blindly inserted catheters using landmarks techniques, is the usual standard of care, to being placed under direct visualization using ultrasound guidance. Since its first use back in the 90's, ultrasound guided insertion of central venous catheters has gained attention and successful attempts have been made to improve this technique [5]. US-guidance initially used acoustic Doppler techniques but is now largely replaced by two-dimensional (2D) imaging and internal jugular vein (IJV) being the preferred site of insertion by US over femoral and subclavian vein [6]. Several studies have compared these two techniques. A meta-analysis done in 1996 by Randolph et al, showed that US-guided technique is superior in terms of attempts rate, failure rates and complication rates [7]. Small-caliber vessels remain a great challenge in the pediatric population which backup the use of imaging modalities for a successful and safer insertion of CVCs; however, a study by Verghese et al., showed 100% success rate for IJV cannulation using 2D US-guided insertion [8]. Another study conducted in 2015 by Goldstein et al., showed that ultrasound guided central line insertion is a safe and effective method to be used in the neonatal age [9].

Furthermore, a study comparing ultrasound-guided central line insertion in the IJV to standard peripherally inserted catheter placement in preterm infants was conducted by Al Hamod et al. (2016) at Saint George Hospital University Medical Center (SGHUMC) division of Neonatology. The RCT evaluated fifty neonates between October 2013 and June 2014 and concluded the superiority of US-guided IJV technique on the rate of first time successful attempt, procedure duration and number of trials when compared to PICC line insertion with no difference concerning the rate of complications [10].

This study aims to develop a better understanding of pain during central line insertions, compare pain scores between the two techniques in order to adopt the less painful technique and ultimately provide insight about the use of analgesics during these procedures for a better outcome.

2. Methods and materials

A single-center prospective randomized controlled study of neonates (preterm and term babies) who underwent an elective or emergent central line insertion between November 2016 and May 2017 was conducted at SGHUMC Neonatal Intensive Care Unit. Hospital's Institutional Review Board approved the study (IRB/O/036-16/1916) and an informed parental consent was signed for study entry. Inclusion criteria included neonates requiring TPN, antibiotic therapy for at least 7 days, and babies with poor or difficult venous access. Exclusion criteria included refusal to sign consent, patients with previously attempted or placed central lines, and patients who were converted from one technique to the other. Patients were randomized into the control and intervention group through a flip of coin each time a patient enrolled in the study

The catheter used for all the patients was an epicutaneo-cava-catheter (ECC), silicone tube material kit, 24G, VYGON® (Aachen, Germany). All procedures were performed under sterile precautions such as hand washing, use of sterile gloves and gowns, facemask, hair cover, and protective eyewear.

The control group consisted of neonates who underwent a PICC line placement. The method of insertion performed followed the procedure previously described by Pettit [11] under local anesthesia using a Lidocaine / Prilocaine 5% emulsion (Emla). Patients in the intervention group underwent US-IJV. This procedure was carried out as follows: The patient's skin was sterilized with chlorhexidine gluconate and the area was infiltrated with local anesthetic agent (lidocaine). Vascular cannulation was performed using the ECC's winged needle. The target vessel was located via the US dynamic (real-time) method. At the point of needle insertion, the ECC was placed through the needle without guide wire placement. Once the catheter was inserted, a gentle aspiration was performed to show blood flow through the 3 ml syringe that was connected to the ECC. The catheter was then secured and fixed with simple steristrips and covered by the transparent dressing [10]. Both techniques were performed by two institutional neonatologists who according to their expertise, one performed all PICC line placements while the other performed all US-IJV.

Transducer selection and the axis of visualization are important to consider in the use of US for ECC, as such a linear 6–13 MHz transducer Sonosite M-turbo was used (manufacturer's recommendations). The transverse view shows the vessel under the transducer and the adjacent structures. The tip of the needle is visualized and inserted at a 45° angle. The longitudinal view helps to track the needle progression toward the IJV. Post procedural chest radiography was done for both groups to confirm placement and evaluate for complications.

The primary outcome measured was the pain score difference between US-guided inserted central line and peripherally inserted central line. The pain score was measured using the Neonatal Pain, Agitation and Sedation Scale (N –PASS). The N-PASS is based on several criteria: crying/irritability, behavior/state, facial expression, extremities/tone and vital signs. Patient characteristics such as gestational age, age, gender, admission diagnosis, weight have been taken into account and the scores were recorded by the nurse in charge of the baby before and during the procedure. Pain score difference was calculated by subtracting the score during the procedure from the pain score before the procedure. The secondary outcome measures included the number of first successful attempts, number of total attempts and procedure duration. Additional patient information collected included gender, TPN administration, gestational age, birth weight and diagnosis.

Sample size calculation: Based on and as a continuation of the study conducted by Al Hamod et al. [10] where US-guided CICC reduced the median procedure time by more than 50% compared to PICC, it is estimated that pain score difference should decrease by at least 1 point. To reduce pain score difference by 1 point, 29 neonates would be needed for every group to produce a study power of 85%.

2.1. Statistical analysis

Analysis was performed using SPSS version 24 (SPSS IBM, New York, USA). Characteristics of patients and outcome measures are described as numbers (%) or median (interquartile range) for nominal and continuous variables, respectively. For each outcome, we compared central line placement using US-guided CICC technique compared to standard PICC placement. The null hypothesis was defined as no difference between the groups. Fisher's exact test was used to compare nominal variables, while continuous variables were compared using Mann–Whitney U-test. The value of $p < 0.05$ was considered statistically significant.

3. Results

A total of 82 neonates were approached for recruitment, 17 of which did not meet the inclusion criteria and the parents of 4 refused to participate (Fig. 1). A final sample of 61 neonates was enrolled in the study. Randomization allocated 32 neonates in the standard PICC group and 29 neonates in the US-guided CICC group. Most of the newborns were males and admitted due to prematurity. The median gestational age for the PICC and US-guided CICC groups were 34.22 and 33.71 weeks, respectively.

There was no statistically significant difference at the level of gender, prematurity at birth, sedation, diagnosis, line indication, pre-procedure pain score, corrected gestational age in weeks, and birth weight between the PICC and the US-guided CICC group (Table 1). US-guided CICC was associated with less pain as reported by the statistically significant lower pain score difference (p-value <0.001) then the standard PICC (Table 2). Additionally, the US-guided CICC had a higher rate of successful first attempt ($p = 0.012$), lower overall number of

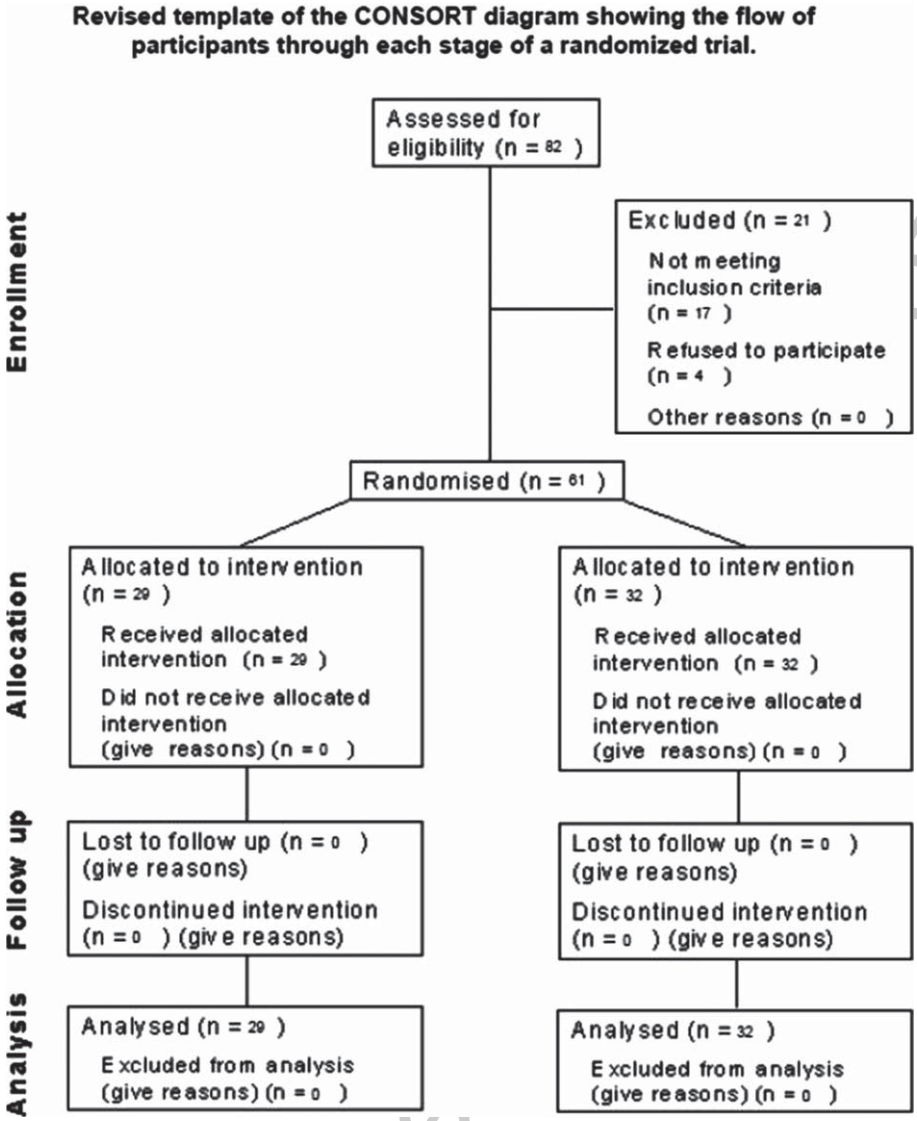

Fig. 1. Consort form.

attempts ($p < 0.001$), and shorter procedure duration ($p < 0.001$) as compared to standard PICC.

4. Discussion

Pain assessment in neonates has gained popularity in the last decade and posed a great challenge to physicians specifically to neonatologists since most of neonatal procedures are practically performed in the neonatal intensive care units (NICU). Despite the fact that transmission of painful stimuli and the maturity of the nervous system responsible for pain are already mature at birth, neonates are unable to verbalize pain and pain assessment is still very primitive. Physiologic indicators of pain have been delineated by the American Academy of Pediatrics and include changes in heart rate, respiratory rate, blood pressure, oxygen saturation, vagal tone, palmar sweating, and plasma cortisol or catecholamine concentrations. Behavioral indicators include crying, change in facial expressions and bodily movements [12].

The statistically significant results shows the dominance of US-guided CICC technique over PICC line insertion in terms of lower pain scores, more number of successful first attempts, less overall number of attempts and shorter procedural duration.

Table 1
Baseline characteristics of recruited neonates

	PICC N (%)	US-guided CICC N (%)	*P*-Value
N	32	29	
Gender			
Male	18 (56.3)	16 (55.2)	1.000[a]
Female	14 (43.8)	13 (44.8)	
Premature at birth			
No	5 (15.6)	5 (17.2)	1.000[a]
Yes	27 (84.4)	24 (82.8)	
Sedation			
No	30 (93.8)	25 (86.2)	0.411[a]
Yes	2 (6.3)	4 (13.8)	
Diagnosis			
LBW	14 (43.8)	12 (44.8)	0.827[a]
Cholestasis	–	2 (6.9)	
Sepsis	2 (6.3)	4 (13.8)	
Respiratory distress	7 (21.9)	5 (17.2)	
Esophageal atresia	1 (3.1)	–	
Pneumonia	2 (6.3)	1 (3.4)	
Hypoglycemia	1 (3.1)	–	
Bladder extrophy	1 (3.1)	–	
Duodenal atresia	1 (3.1)	–	
Hirschsprung	1 (3.1)	–	
Seizure	–	1 (3.4)	
Gastroschisis	1 (3.1)	1 (3.4)	
Jaundice	1 (3.1)	2 (6.9)	
Line indication			
TPN	11 (34.4)	11 (37.9)	0.433[a]
TPN+Abx	14 (43.8)	10 (34.5)	
Abx	5 (15.6)	8 (27.6)	
Abx+Inotropes	2 (6.3)	–	
Pre-procedure pain score			
Median (Q1–Q3)	1 (0– 1)	1 (0–2)	0.541[b]
Minimum-maximum	–3–3	–3–3	
Corrected gestational age in weeks			
Median (Q1–Q3)	34.22 (31.29–37.64)	33.71 (29.64–38.14)	0.789[b]
Minimum-maximum	27.14–40	27.14–39.71	
Birth weight (grams)			
Median (Q1–Q3)	1395 (1177–2575)	1300 (985–2500)	0.398[b]
Minimum-maximum	810–4000	710–3100	

[a] fisher exact; [b] Mann-Whitney U test.

By decreasing the procedural duration and the number of attempts, neonates are exposed to pain for a shorter duration of time. In our study, US-guided CICC was considered the superior procedure to be used when a central line is needed in the neonatal age.

Pain management was accomplished by using local anesthesia and only few received sedation for agitation (4 in the PICC group and 2 in the US-guided CICC group, p-value = 0.411). However, the use of sedation didn't interfere with our pain scores although the number of patients sedated was too small. Although, the difference might be also related to the different types of local anesthesia used in each group and their effectiveness (Lidocaine emulsion vs lidocaine infiltration).

A single study was found in the literature that measures pain during the placement of a PICC. This study was an exploratory prospective study that used premature infant pain profile (PIPP) assessment tool to measure pain. This study concluded that the use of analgesic medications is imperative in controlling pain during neonatal invasive procedures such as PICC insertion [13]. Although, the effect of sedation on the developing brain and concerns over neurotoxicity have been clearly cited in several studies, providing effective analgesia and aiming to reduce pain in neonates is imperative as pain itself has an adverse outcome on neurodevelopment in the neonatal period [14]. The control of pain in neonates is of great value to diminish the acute and long-term outcomes of sedation, especially those related to the

Table 2
Results of central line placement using ultrasound guided CICC technique compared to standard PICC placement

	PICC (N = 32) N (%)	US-guided CICC (N = 29) N (%)	*P*-Value
Pain score difference			
Median (Q1–Q3)	4 (4–5)	2 (1–3)	<0.001[b]
Minimum-Maximum	2–7	0–5	
Success in first attempt			
No	27 (84.4)	15 (51.7)	0.012[a]
Yes	5 (15.6)	14 (48.3)	
Number of attempts			
Median (Q1–Q3)	4 (2–4.75)	2 (1–2)	<0.001[b]
Minimum-maximum	1–7	1–4	
Procedure duration			
Median (Q1–Q3)	39 (26.5–50.5)	16 (12–19)	<0.001[b]
Minimum-maximum	14–57	9–38	

[a]fisher exact; [b]Mann-Whitney U test.

nervous system. The exposure to pain due to procedures in the NICU has been linked to several adverse neurodevelopmental outcomes as poorer cognitive and motor scores, impairment of growth, reduced white matter and subcortical gray matter maturation, and altered corticospinal tract structures [15].

Therefore, taking the results of our previous study showing no difference in the rate of complications during insertion [10] and the findings from this trial, the use of US guided CICC technique would probably be the better option in successfully providing a central line access for neonates with the least pain possible.

5. Conclusion

US-guided CICC in neonates is a less painful alternative technique of inserting a central line than the standard PICC line. In parallel with decreased insertion trials, less operative time and more successful first attempts, US guidance assist health care providers in the NICU to decrease the exposure of neonates to noxious stimuli and less use of analgesics.

Clinical trial registry

ClinicalTrials.gov NCT03647293.

Funding source

No external funding of this manuscript.

Financial disclosure

All authors have indicated they have no financial relationships relevant to this article to disclose.

Conflict of interest

All authors have indicated they have no potential conflicts of interest to disclose.

References

[1] Trieschmann U, Udink ten FC, Sreeram N. Central venous catheters in children and neonates- what is important? Images Paediatr Cardiol. 2007;9(4).
[2] Cheung E, Baerlocher M, Asch, M, Myers, A. Venous Access. A practical review for 2009. Can Fam Physician. 2009;55(5):494-6.
[3] Taylor RW, Palagiri AV. Central venous catheterization. Crit Care Med. 2007;35:1390-6.
[4] Bhatt S, Dahat A, Jain N, Nayak, U, Patel V. Indications and complications of central venous catheterization in critically ill children in intensive care unit. National Journal of Medical Research. 2012;2:1.85-8.
[5] Kumar A, Chuan A. Ultrasound guided vascular access. Best Pract Res Clin Anesthesiol. 2009;23:299-311.
[6] Hind D, Calvert N, McWilliams R, et al. Ultrasonic locating devices for central venous cannulation: Meta-analysis. BMJ. 2003;327(7411):361.
[7] Randolph AG, Cook DJ, Gonzales CA, Pribble CG. Ultrasound guidance for placement of central venous catheters: A meta-analysis of the literature. Crit Care Med. 1996;24:2053-8.
[8] Verghese ST, McGill WA, Patel RI, Sell JE, Midgley FM, Ruttimann UE. Ultrasound-guided internal jugular venous cannulation in infants. Anesthesiology. 1999;91:71-7.
[9] Goldstein SD, Pryor H, Salazar JH, Dalesio N, Stewart FD, Abdullah F, Colombani P, Lukish JR. Ultrasound-guided percutaneous central venous access in low birth weight infants: Feasibility in the smallest of patients. J Laparoendosc Adv Surg Tech A. 2015;25(9):767-9.
[10] Al Hamod DA, Zeidan S, Al Bizri A, Baaklini G, Nassif Y. Ultrasound-guided central line insertion and standard peripherally inserted catheter placement in preterm infants: Comparing results from prospective study in a single-center. North Am J Med Sci. 2016;8:205-9.
[11] Pettit J. Technological advances for PICC placement and management. Adv Neonatal Care. 2007;7:122-31.
[12] American Academy of Pediatrics. Preventions and management of pain in the neonate: An update. Pediatrics. 2006;118:2231-41.
[13] Costa P, Camargo P, Bueno M, Kimura A. Measuring pain in neonates during placement of central line catheter via peripheral insertion. Acta Paul Enferm. 2010;23(1):35-40.
[14] Davidson A, Flick RP. Neurodevelopment implications of the use of sedation and analgesia in neonates. Clin Perinatol. 2013;40(3):559-73.
[15] Walker SM. Neonatal pain. Pediatric Anesthesia. 2014; 24:39-48.