

# Perforation and right ventricular outflow tract stenting: Alternative palliation for infants with pulmonary atresia/ventricular septal defect

David Aurigemma MD  | John W. Moore MD, MPH | Gabrielle Vaughn MD |  
Nasser Moiduddin MD | Howaida G. El-Said MD, PhD 

Rady Children's Hospital, San Diego,  
University of California, San Diego,  
California, USA

## Correspondence

David Aurigemma, Rady Children's Hospital,  
3020 Children's Way, San Diego, CA  
92123.  
Email: daurig04@gmail.com

## Abstract

**Background:** Right ventricular outflow tract (RVOT) stents have been used as palliation in patients with severe tetralogy of Fallot (TOF). Radiofrequency perforation of the RVOT has also been described in patients with pulmonary atresia (PA)/ventricular septal defect (VSD). However, RVOT stenting in conjunction with radiofrequency perforation as a means for establishing reliable pulmonary blood flow in patients with PA/VSD has not previously been reported.

**Objectives:** Our aim is to report our experience with using perforation of plate-like pulmonary valve atresia combined with stenting of RVOT as an alternative and equally efficacious intervention for infants with PA/VSD, as compared to a surgical pulmonary artery shunt (SPS).

**Methods:** A retrospective review of patients with PA/VSD at our institution from Jan 2006 to October 2015 was performed.

**Results:** Twenty-seven patients received palliation for PA/VSD. Five (median 2.5 kg, 2.1-4.1 kg) underwent RVOT stenting and 22 (3.5 kg, 2.1-4.6 kg) underwent surgical SPS. Of the patients who received an RVOT stent, 3 underwent guidewire perforation and balloon dilation of the plate-like pulmonary valve, and 2 underwent radiofrequency perforation of the pulmonary plate, followed by balloon dilation. Postprocedure saturations averaged 93% in the stent group and 89% in the shunt group. One of the patients who underwent RVOT stenting required additional stenting of the PDA for isolation of the LPA, but none required re-intervention. Four patients in the SPS cohort required re-intervention (18%). Two required stenting of the shunt, and 2 required surgical revision of the shunt. There was one death in the stent group, however this was secondary to withdrawal of support given an underlying genetic diagnosis (trisomy 13). There was one fatality in the SPS cohort prior to hospital discharge.

**Conclusions:** Perforation followed by RVOT stenting may be a safe and effective alternative to surgical SPS in infants with PA/VSD.

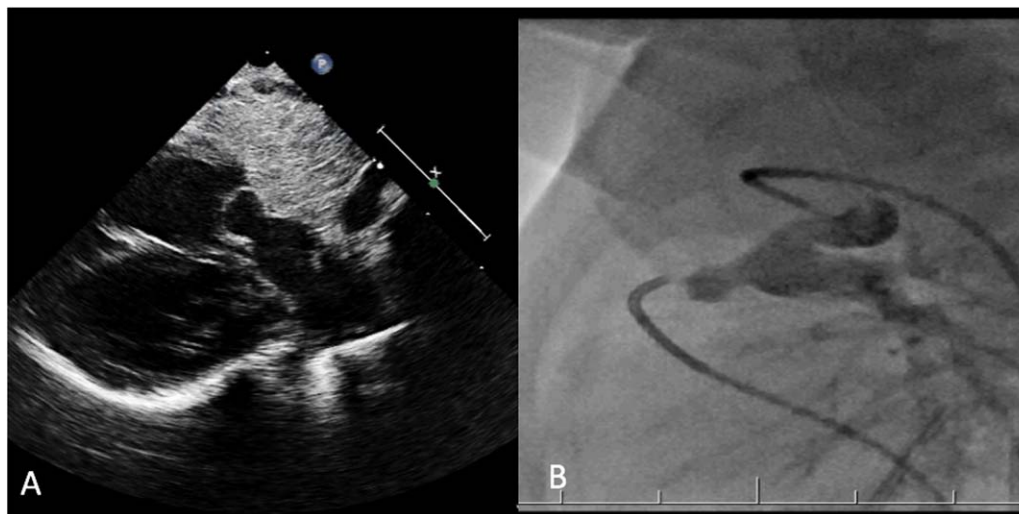
## KEYWORDS

BT shunt, pulmonary atresia, stent, tetralogy of Fallot

## 1 | INTRODUCTION

The surgical systemic to pulmonary artery shunt (SPS) is a well-established technique to provide pulmonary blood flow in infants with cyanotic congenital heart disease.<sup>1</sup> However, in a contemporary study

Petrucci et al reported a 7.2% mortality and 13.1% morbidity in a cohort of more than 1200 infants undergoing modified Blalock-Taussig shunt (mBTs) as neonates.<sup>2</sup> With development of catheter based interventional techniques, alternative methods of establishing and securing reliable pulmonary blood flow may be achieved at



**FIGURE 1** Demonstrates a plate-like pulmonary valve atresia with an adequate RVOT/MPA to support perforation, balloon dilation, and stenting. The preprocedural echocardiographic image (A) is correlated with intra-procedural angiography via PDA injection (B)

lower risk. There are reports of stenting the right ventricular outflow tract (RVOT) in patients with tetralogy of Fallot (TOF).<sup>3</sup> There are also small case series describing radiofrequency perforation with balloon dilation of the RVOT in patients with PA/VSD.<sup>4</sup> However, there are no reports of RVOT stenting in conjunction with perforation in neonates with PA/VSD. Our aim is to report our experience with using perforation of plate-like pulmonary valve atresia combined with stenting of RVOT as an alternative and equally efficacious intervention for infants with PA/VSD.

## 2 | METHODS

The research plan was approved by the UCSD and Rady Children's Hospital Institutional Review Board. Patients at our institution with plate-like atresia of the pulmonary valve associated with a ventricular septal defect presenting between January 2006 and January 2016 were identified. In all cases the diagnosis was made based on standard imaging techniques (echocardiography, computed tomography, angiography, etc) whereby an imperforate RVOT was noted in conjunction with a conoventricular VSD. Patient medical records were reviewed. Demographic, echocardiographic, catheterization, and clinical data were collected and analyzed.

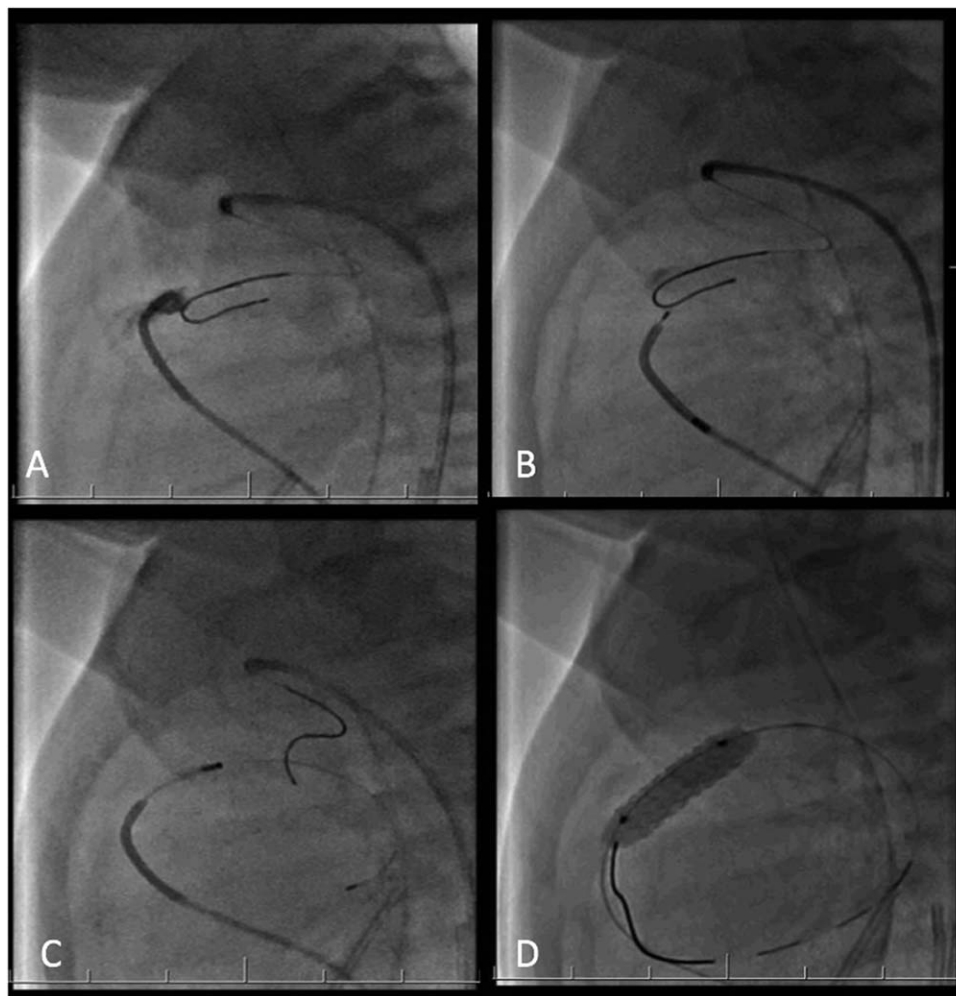
The decision to proceed with SPS or catheter based intervention was individualized. A multidisciplinary approach to the palliative strategy was undertaken. High risk patients were evaluated for percutaneous intervention. Infants were deemed high risk if they were <3.0 kg, had significant comorbid medical conditions, suspected chromosomal abnormalities, or had parental religious beliefs that precluded blood product administration.

Procedural success was defined as establishment of adequate pulmonary blood flow without the requirement for urgent, unplanned re-intervention within 24 hours.

### 2.1 | RVOT stenting

Based on echocardiographic evaluation of the RVOT and main pulmonary artery (MPA), patients were excluded for percutaneous intervention if their anatomy was unfavorable (small/absent RVOT, increased distance between RVOT and MPA segment, no discreet plate-like valve, etc.) (Figure 1). Access was obtained in the femoral vessels in standard fashion with 4F short sheaths. A 4F Bern C (Meritt Medical Systems, South Jordan, UT) catheter or 4F JR 1 (Cook Medical Inc, Bloomington, IN) catheter was advanced through the venous sheath and placed in the RVOT. A 4F Angled Glide (Terumo Medical, Somerset, NJ) catheter was advanced through the arterial sheath and positioned at the mouth of the patent ductus arteriosus (PDA). A hand injection was performed through the catheter at the mouth of the PDA in order to assess the diameter and length of the MPA.

As the PDA was the only source of pulmonary blood flow, care was taken to avoid spasm of the PDA. Rather than using a snare system to cross the PDA, a 0.014 BMW (Abbott Vascular, Santa Clara, CA) wire was advanced through the Angled Glide catheter, across the PDA, and placed in the MPA segment to act as a target (Figure 2A). A second 0.014 BMW wire was then advanced into the venous catheter positioned in the RVOT. The wire was first used to probe the plate-like valve in an attempt to perforate the tissue, gaining access to the MPA. If the guide-wire could not be passed through the plate-like tissue, it was removed and a 4F radiofrequency system (Baylis Medical, Montreal, Canada) was then advanced through the venous catheter into the RVOT (Figure 2B). Under fluoroscopic guidance, the RF catheter was advanced towards the BMW wire in the MPA, using 10 Watts of energy for 2 second intervals (range 2–5 intervals). Upon successful perforation, the RF wire was advanced into a branch pulmonary artery. The RF system was exchanged over the RF wire and the Bern C/JR 1 catheter was advanced into the branch pulmonary artery (Figure 2C). The RF wire was then exchanged for an 0.014 Iron Man (Boston Scientific, Natick, MA) wire, which was used to establish secure position in the branch PAs.



**FIGURE 2** Demonstrates a step-wise approach with (A) positioning of glide catheter in the RVOT proximal to the plate-like pulmonary valve, with 0.014 BMW wire positioned in the MPA via the PDA. (B) The Bayliss RF system is positioned in the RVOT, and (C) after successful perforation, the RF wire is positioned in the LPA. After exchange of wire (D) a Formula 418 5 × 16 stent is deployed across the RVOT

Subsequently, a balloon catheter was advanced over the Iron Man wire to dilate the plate-like valve. The purpose of initial balloon dilation was to ensure an adequate opening to allow passage of a long sheath, rather than to dilate the valve fully. Thus, 3–4 mm coronary balloon catheters were selected because of their low profiles, independent of

preprocedure measurements. Balloons utilized included a 3 mm Monorail (Boston Scientific), Trek (Abbott Vascular, Santa Clara, CA), and Sprinter (Medtronic, Minneapolis, MN). A 3.5-mm Sprinter Legend (Medtronic) was used in two patients, and a 4 mm Monorail balloon was used in one patient (Table 1). The balloons were between 12 and 15 mm in

**TABLE 1** Catheterization and technical data

Patient	Weight	MPA diameter	Balloon type/size	Stent type/size
1	2.1 kg	4.0 mm	Monorail coronary, 3 mm x 15 mm; Monorail Coronary 4 mm x 15 mm	Formula 418 5 mm x 20 mm
2	2.5 kg	3.8 mm	Sprinter coronary 3.5 mm x 15 mm	Rebel 4.5 mm x 16 mm
3	4.1 kg	6.1 mm	Trek coronary 3 mm x 12 mm	Formula 418 5 mm x 20 mm
4	2.6 kg	5.0 mm	Sprinter coronary 3 mm x 12 mm	Formula 418 5 mm x 16 mm
5	2.7 kg	3.9 mm	Sprinter coronary 3.5 mm x 15 mm	Formula 418 5 mm x 16 mm

length. The balloons were advanced over the Iron Man wire and inflated a total of 4–6 times.

Following dilation, the 4F venous short sheath was removed, and was replaced with a 4F 45-cm long sheath (Check Flow Performer-CHB, Cook Medical Inc), with tip positioned into the MPA. A stent was selected based on echocardiographic and angiographic measurement of the MPA. The diameter of the stent selected was  $\pm 1$  mm of the MPA as measured just above the atretic pulmonary valve. The length was selected to allow the stent to span the RVOT, pulmonary valve, and into the distal MPA, while not encroaching on the branch PAs (Figure 2D). Four stents were 5 mm in diameter (Formula 418 stent, Cook Medical Inc), and one stent was 4.5 mm in diameter (Rebel Coronary Stent, Boston Scientific). Three stents were 16 mm long, and 2 were 20 mm long (Table 1).

One patient required stenting of the PDA 24 hours following stenting of the RVOT. This patient's family had religious beliefs that precluded the use of blood products and was the primary reason why catheter intervention was selected for initial palliation. The anatomy of this patient's pulmonary arteries was such that it was not clear whether the LPA might be threatened as the PDA closed. Given the scenario of an infant with clinically inadequate pulmonary blood flow and religious beliefs that would not allow for blood product administration, a multidisciplinary team concluded that a palliative procedure to stent the RVOT was indicated, with close observation with respect to LPA patency in the immediate postprocedural period. Prostaglandin was discontinued at the completion of the case. Subsequently, the patient became increasingly desaturated. Echocardiography demonstrated severe LPA stenosis and a small PDA. Prostaglandin was restarted, and stenting of the PDA to maintain patency of the LPA was undertaken the following day.

Procedures were conducted with prostaglandin infusion to ensure ductal patency. Patients received heparin during the procedure to maintain activated clotting time (ACT) of 190–220 per institutional protocol. Heparin was continued at 10  $\mu$ /kg/hour for 24 hours post procedure, after which patients were started on aspirin. Prophylactic antibiotics were administered to all patients.

## 2.2 | Systemic to pulmonary artery shunt

Surgical shunting is a well-established procedure. The type, location, and size of the shunt were determined by the operating surgeon in each individual case. PDA ligation was also performed. Three patients also had patch reconstruction of the pulmonary arteries during the procedure, and one patient underwent resection of a right upper lobe lung mass.

Of 22 patients that underwent SPS, 12 (54.6%) were modified Blalok-Taussig shunts (mBTS), and 10 (45.4%) were central shunts. Shunt diameters were 3.5 mm in diameter in 13 patients, 4 mm in 6 patients, 3 mm in 2, and 1 was 5 mm in diameter.

## 2.3 | Statistics

Discrete variables were summarized as percentages. Continuous variables were summarized as mean with standard deviation. A two sample t-test was used to determine if the means are significantly different

**TABLE 2** Demographic information of both groups

	Stent (n = 5)	Shunt (n = 22)	P value
Age in days (range)	17 (2–34)	16 (2–83)	0.94
Male, N (%)	4 (80)	15 (68)	0.62
Gestational age, months + days	38 + 2	37 + 5	0.57
Weight, kg (range)	2.5 (2.1–4.1)	3.5 (2.1–4.6)	0.32
RPA diameter, cm	0.44 $\pm$ 0.04	0.42 $\pm$ 0.08	0.94
RPA Z-score	–0.69 $\pm$ 0.24	–0.41 $\pm$ 0.12	0.89
LPA diameter, cm	0.45 $\pm$ 0.05	0.40 $\pm$ 0.12	0.43
LPA Z-score	–0.28 $\pm$ 0.52	–0.45	0.47

across groups for continuous covariates and a chi-square test was used for categorical covariates. Statistical analysis was computed using R (v. 3.3.1), with a *P* value  $< .05$  considered statistically significant.

## 3 | RESULTS

Twenty-seven patients with PA/VSD were identified. Fifteen (68.2%) were male. Five patients underwent RVOT stenting, and 22 underwent SPS. The median weight between the two groups was not significantly different (2.5 kg in RVOT stent group vs 3.5 kg in the SPS group). There were no statistical differences in age at procedure, gestational age, or body surface area between the two groups (Table 2).

### 3.1 | Procedural outcomes

All 5 RVOT stent procedures were successful, whereas 20/22 SPS procedures were successful (*P* = .5) (2 patients required urgent re-intervention within 24 hours). Oxygen saturations increased in the RVOT stent group from 86%  $\pm$  10% to 93%  $\pm$  8%, whereas it increased from 87%  $\pm$  4% to 89%  $\pm$  6% in the SPS group (*P* = .23). This difference was not statistically significant. The median length of stay in the RVOT stent group was 27.6 days  $\pm$  17.8 and 34.6 days  $\pm$  28.3 in the SPS group (*P* = .61). With respect to branch pulmonary arteries, there was no difference between the two groups in pre- and postprocedural diameters (Table 3).

There were no unplanned reinterventions in the RVOT stent group. In the SPS group, 5/22 patients required reintervention (*P* = .11). One patient required urgent shunt revision within 4 hours of the initial

**TABLE 3** Patient outcomes

	Stent (n = 5)	Shunt (n = 22)	P value
Procedural success (%)	5/5 (100)	20/22 (91)	0.50
Preoperative oxygen saturation	85.8 $\pm$ 9.6	86.8 $\pm$ 4.4	0.73
Postoperative oxygen saturation	93.0 $\pm$ 7.8	89.4 $\pm$ 5.5	0.23
Length of stay, days (range)	28 (9–53)	36 (9–125)	0.61
Acute reintervention (%)	0/5 (0)	5/22 (23%)	0.11
Mortality (%)	0/5 (0)	1/22 (5)	0.64

**TABLE 4** Complete repair surgical data

	Stent (n = 4)	Shunt (n = 17)	P value
Age in days (range)	146(107–205)	199(93–255)	0.14
Cardiopulmonary bypass time, min	161 ± 56	179 ± 85	0.48
Aortic cross clamp time, min	86 ± 48	70 ± 40	0.41

procedure for persistent hypoxemia. Another patient required PA reconstruction, and extracorporeal membrane oxygenation (ECMO) within 24 hours of the initial procedure. One patient required urgent chest exploration for persistent bleeding 5 hours after the SPS procedure. Two patients required stenting of their shunt at 11 and 13 days post procedure.

There were no in hospital deaths in the RVOT stent group. However, one patient was diagnosed with Trisomy 13 following the RVOT stent procedure, and elected hospice care. This patient died a natural death at home following discharge, as supportive care was withdrawn. There was 1 in hospital death (4.5%) in the SPS group, which occurred secondary to an acute aspiration event, and was not associated with the surgical shunt procedure ( $P = .64$ ) (Table 3).

### 3.2 | Complete repair

All patients, except the 2 fatalities noted earlier, have undergone complete repair. There was no difference in the age at which complete repair occurred between groups. Infants who underwent RVOT stenting were repaired at  $146.5 \pm 43.8$  days, and those who underwent SPS were repaired at  $198.7 \pm 64$  days ( $P = .14$ ). In the RVOT stent group, cardiopulmonary bypass time was  $160.8 \pm 56$  minutes and aortic cross-clamp time was  $86 \pm 47.6$  minutes. The cardiopulmonary bypass time and aortic cross clamp time in the SPS group was  $179 \pm 43.7$  minutes and  $69.6 \pm 31.7$  minutes. There were no differences noted between the groups (Table 4)

## 4 | DISCUSSION

There have been several case series reporting catheter based establishment of antegrade pulmonary blood flow in infants who would have otherwise received a surgical shunt.<sup>5–9</sup> These reports demonstrate that the technology to carry out these interventions is available. However, there is not sufficient data available to demonstrate that these interventions are as effective and safe as standard surgical procedures.

Our experience suggests that valve perforation with balloon dilation of the pulmonary valve, and stenting of the RVOT in infants with PA/VSD may be an effective alternative to SPS. Our data also suggest possible equity with respect to procedural outcomes, morbidity, mortality, or complications with complete repair. Though infants in this study share the same underlying diagnosis, it is important to note that they were selected to undergo catheter based intervention because they were judged to be at higher risk for surgical complications.<sup>10–14</sup> The statistical analysis of the two groups does not readily reflect the perceived risk

profile of the patients selected to undergo catheter based intervention, which is primarily due to the small cohort size. Four of the 5 patients were  $<3.0$  kg (one of which was 2.7 kg and had physical features suggestive of an underlying chromosomal anomaly later confirmed as trisomy 13), and the one patient  $>3.0$  kg (4.1 kg at the time of the procedure) came from a family with religious beliefs that precluded blood product administration. Though not a traditional risk factor for undergoing SPS, it was nonetheless perceived as such within the clinical context.

There was concern in our group that presence of a RVOT stent would complicate later surgical repair. Our experience suggests otherwise, as there was no difference in timing of repair, nor was there difference in length of operation. Furthermore, previous reports of infants undergoing RVOT stenting suggested that complete resection of stent material might be difficult.<sup>3</sup> Of the 4 patients who underwent RVOT stenting in our cohort, residual stent material was left in only one patient, who retained small stent struts embedded into the posterior wall of the MPA. Resection of stent from the RVOT also did not appear to increase the incidence of intraoperative arrhythmia, as only one patient had a significant arrhythmia (Junctional ectopic tachycardia), whereas pathological rhythms occurred in four patients who underwent complete repair following SPS (18%).

The primary limitation of this study lies in the small cohort size. Though there appear to be trends between groups (length of stay, postprocedural saturations, reintervention), statistical significance was not achieved. With analysis of a larger patient population, trends may be further elucidated.

## 5 | CONCLUSION

This patient experience suggests that perforation followed by RVOT stenting may be a safe and effective alternative to surgical SPS in infants with PA/VSD.

### CONFLICT OF INTEREST

There are no conflicts of interest.

### AUTHOR CONTRIBUTIONS

*Primary author of the article. Responsible for collecting data, drafting initial manuscript, editing manuscript, and submitting manuscript:* David Aurigemma

*Responsible for initial study design and concept. Reviewed and edited initial manuscript, and reviewed/approved final version:* John W. Moore  
*Collection of study data. Reviewed and edited initial manuscript:* Gabrielle Vaughn, Nasser Moiduddin

*Responsible for initial study design and concept. Reviewed and edited initial manuscript, figures, tables, and reviewed/edited/approved final version:* Howaida El-Said

### ORCID

David Aurigemma MD  <http://orcid.org/0000-0003-3028-3147>

Howaida G. El-Said MD, PhD  <http://orcid.org/0000-0002-3447-7398>

## REFERENCES

- [1] Williams J, Bansal A, Cameron D, et al. Two thousand Blalock-Taussig shunts: a six-decade experience. *Ann Thorac Surg.* 2007;84(6):2070–2075.
- [2] Petrucci O, O'Brien SM, Jacobs ML, et al. Risk factors for mortality and morbidity after the neonatal Blalock-Taussig shunt procedure. *Ann Thorac Surg.* 2011;92(2):642–652.
- [3] Stumper O, Ramchandani B, Noonan P, et al. Stenting of the right ventricular outflow tract. *Heart.* 2013;99(21):1603–1608.
- [4] Walsh MA, Lee K-J, Chaturvedi R, Van Arsdell GS, Benson LN. Radiofrequency perforation of the right ventricular outflow tract as a palliative strategy for pulmonary atresia with ventricular septal defect. *Catheter Cardiovasc Interv.* 2007;69(7):1015–1020.
- [5] Mallula K, Vaughn G, El-Said H, Lamberti JJ, Moore JW. Comparison of ductal stenting versus surgical shunts for palliation of patients with pulmonary atresia and intact ventricular septum. *Catheter Cardiovasc Interv.* 2015;85(7):1196–1202.
- [6] Dohlen G, Chaturvedi RR, Benson LN, et al. Stenting of the right ventricular outflow tract in the symptomatic infant with tetralogy of Fallot. *Heart.* 2009;95(2):142–147.
- [7] Min-Jung C, Kil-Ho B, Hyoung-Doo L, et al. Catheter-based treatment in patients with critical pulmonary stenosis or pulmonary atresia with intact ventricular septum: a single institute experience with comparison between patients with and without additional procedure for pulmonary flow. *Congenit Heart Dis.* 2013;8:440–449.
- [8] Humpl T, Soderberg B, Benson L, et al. Percutaneous balloon valvotomy in pulmonary atresia with intact ventricular septum. *Circulation.* 2003;108(7):826–832.
- [9] Gibbs J, Uzun O, Dickinson D, et al. Right ventricular outflow stent implantation: an alternative to palliative surgical relief of infundibular pulmonary stenosis. *Heart.* 1997;77(2):176–179.
- [10] Curzon C, Milford-Beland S, Jagers J, et al. Cardiac surgery in infants with low birth weight is associated with increased mortality: analysis of the society of thoracic surgeons congenital heart database. *J Thorac Cardiovasc Surg.* 2008;135(3):546–551.
- [11] Kalfa D, Krishnamurthy G, Bacha E, et al. Outcomes of cardiac surgery in patients weighing <2.5 kg: affect of patient-dependant and -independent variables. *J Thorac Cardiovasc Surg.* 2014;148:2499–2506.
- [12] Bové T, François K, De Groote K, et al. Outcome analysis of major cardiac operations in low weight neonates. *Ann Thorac Surg.* 2004;78(1):181–187.
- [13] Ferry P. Neurologic sequelae of open-heart surgery in children. *AJDC.* 1990;144(3):369–373.
- [14] Takahiko S. Current status of brain protection during surgery for congenital cardiac defect. *Gen Thorac Cardiovasc Surg.* 2016;64(2):72–81.

**How to cite this article:** Aurigemma D, Moore JW, Vaughn G, Moiduddin N, El-Said HG. Perforation and right ventricular outflow tract stenting: Alternative palliation for infants with pulmonary atresia/ventricular septal defect. *Congenital Heart Disease.* 2017;00:1–6. <https://doi.org/10.1111/chd.12552>